

An indurated plaque on right side of chest – a first sign of underlying breast carcinoma

W R H P Dayananda¹, B E S Dahanayake², W N C Perera³

Sri Lanka Journal of Dermatology, 2022-2023, 23: 42-43

Abstract

Previously undiagnosed visceral malignancy may rarely present for the first time as cutaneous metastases. Given their variable clinical presentation early diagnosis is often challenging. We report a case of primary breast carcinoma presenting as cutaneous metastases.

Introduction

Cutaneous metastases are uncommon and rarely may manifest as the presenting sign of previously undiagnosed malignancy¹. In women, breast carcinoma is the most common tumor leading to skin metastases^{1,2}. We report a case of cutaneous metastases secondary to underlying breast carcinoma presenting with an asymptomatic indurated plaque on the chest wall.

Case report

A 67-year-old lady presented to the dermatology clinic with 2-week history of an asymptomatic erythematous lesion over the right upper chest. She did not have a past history of malignancy or tuberculosis and denied constitutional symptoms.

On examination there were erythematous papules and nodules coalesced into an indurated plaque over the right upper chest wall (Figure 1). On further examination, she was found to have ipsilateral swollen erythematous breast with overlying skin having evidence of induration with *peau d'orange* appearance (Figure 2) and regional lymphadenopathy.

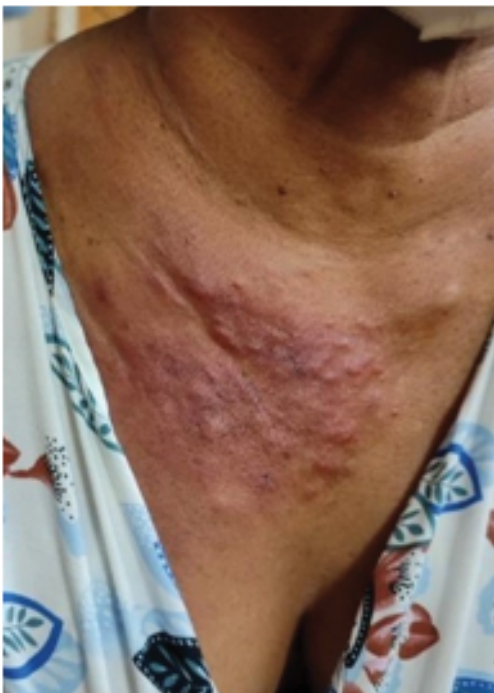

Figure 1.

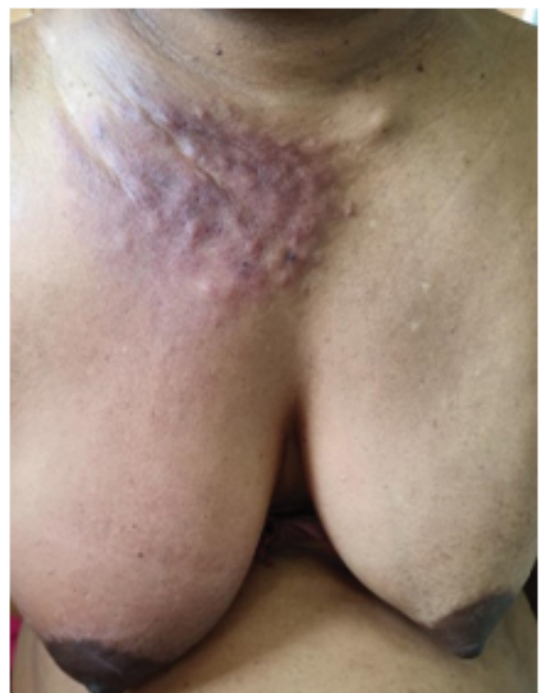

Figure 2.

^{1,2}Registrar in Dermatology, ³Consultant Dermatologist, Colombo South Teaching Hospital, Kalubowila, Sri Lanka.

Skin biopsy revealed dermal infiltration of tumor cells and intravascular tumor emboli within dermal lymphatics (Figure 3). Immunohistochemistry was negative for estrogen and progesterone receptors. The patient was referred for oncological care where her diagnosis was confirmed histologically by guided biopsies from the right breast and axillary lymph node. CT scan revealed right breast carcinoma with nodal, cutaneous, and adrenal metastases.

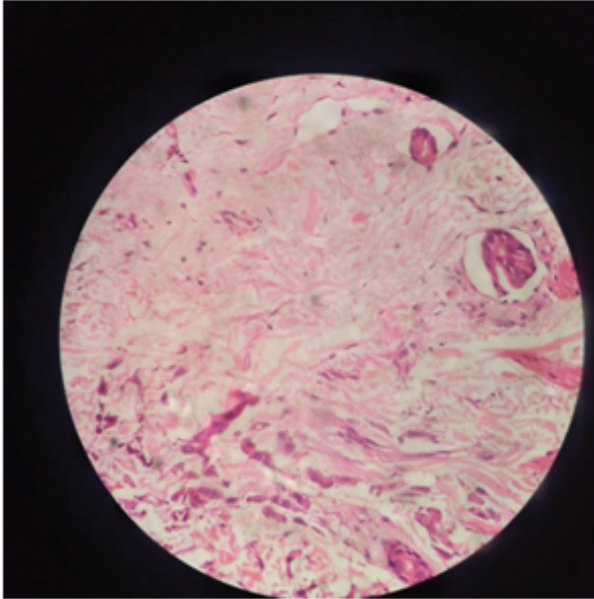


Figure 3.

Discussion

Cutaneous metastases account for 10% of metastatic disease and in 1% of cases it is the presenting manifestation of undiagnosed malignancy³. In women, breast carcinoma is the most common malignancy that metastasizes to skin followed by melanoma, and carcinomas of the ovary, lung, head

and neck¹. Methods of spread include hematogenous and lymphatic dissemination as well as direct extension.

Cutaneous metastases due to breast carcinoma present with a wide array of clinical manifestations including dermal and subcutaneous nodules, erythematous patches of carcinoma erysipeloides, woody induration with a *peau d'orange* appearance (*En cuirasse*), dermatitis-like appearance of paget disease, scalp plaques with alopecia and carcinoma telangiectodes. The most common presentation is asymptomatic nodules on the ipsilateral chest wall and breast³. Our patient presented with several of the above manifestations including skin nodules over the chest wall and a mixed pattern of carcinoma erysepeloides with *peau d'orange* appearance over the breast.

In primary breast carcinoma, skin metastases indicate advanced disease and poor prognosis⁴.

Conclusion

Primary breast carcinoma may present as cutaneous metastases as its initial manifestation and may present with multiple clinical morphologies in the same patient.

References

1. Bologna JND. *Dermatology* 2: 2162.
2. Bittencourt MJS, Carvalho AH, Nascimento BAM, Freitas LKM, Parijós AM. Cutaneous metastasis of a breast cancer diagnosed 13 years before. *An Bras Dermatol*. 2015.
3. Cohen PR. Pleomorphic Appearance of Breast Cancer Cutaneous Metastases. *Cureus*. 2021; 13(12): e20301.
4. Harwin Prestasia Putra, *et al*. Cutaneous lesions as the first manifestation of breast cancer: a rare case. *Pan African Medical Journal* 2020; 37(383).