

# Isolated leg hair involvement in lichen planopilaris

K D T Dinupa<sup>1</sup>, W K B A Fernando<sup>2</sup>, B E S Dahanayaka<sup>2</sup>, W N C Perera<sup>3</sup>

*Sri Lanka Journal of Dermatology*, 2021, 22: 73-75

## Abstract

Lichen planopilaris (LPP) is the follicular representation of lichen planus which is the prototype of CD8+ T cell mediated inflammatory diseases. In all the variants of LPP clinical hallmark is the scarring alopecia of involved hair follicles in which the scalp hair is the main target. Though the non-inflammatory type alopecia is documented in certain subtypes such as l'assueur-graham-little-piccardi (LGLP) and frontal fibrosing cicatricial alopecia (FFA) where it particularly affects the body hair, scarring alopecia of body hair is extremely rare in LPP. Herein we report a case of isolated leg hair involvement in LPP.

## Introduction

Scarring alopecia is one of the most feared dermatological conditions a patient can have. Under the umbrella of scarring alopecia there are many aetiologies to be discovered on the clinical grounds and investigations. Accurate diagnosis is the key to the proper treatment. Clinical diagnosis and subsequent histological confirmation are integral parts in the process of diagnosis. Incidence of aetiologies is not precisely described on literature. However, the incidence of lichen planopilaris (LPP) seems to be top in the list. Isolated body hair (leg) involvement is extremely rare in LPP and can be easily mistaken for other follicular diseases such as dermatitis cruris pustulosa et atrophicans (DCPA), lichen spinulosus and follicular eczema. Herein we report a case of isolated leg hair involvement in LPP.

## Case report

A 25 year old previously healthy patient presented to our department with progressive loss of leg hair since the age of fifteen. There was no associated hair loss in the scalp and other hair bearing areas. Intensely itchy papular lesions over the hair follicle of the leg was the only symptom he had. He denied any itchy lesions elsewhere on the skin or mucosal lesions suggestive of lichen planus. Initial pruritic lesions were patchy and distributed over the distal part of both legs and gradually extended proximally up to

the lower thigh level. He denied significant chronic pustular lesions over the legs suggestive of DCPA<sup>4</sup>. But for the past two years there was no significant progression of the cutaneous lesions but on and off few itchy skin lesions occurred continuously. He denied any family history of similar condition and symptoms suggestive of lupus spectrum of disorders.

On examination most of the hair follicles of both legs and lower thighs were replaced with atrophic scars and few remained follicles showed perifollicular scaling. There were few keratotic follicular papules distributed over the legs and there were only one or two pustules. Dermatoscopic examination revealed perifollicular scaling and erythema, tubular structures covering proximal hair shaft and atrophic whitish scars which have replaced the follicular unites. Other body and scalp hair were spared and rest of the skin and appendages were normal to the examination.

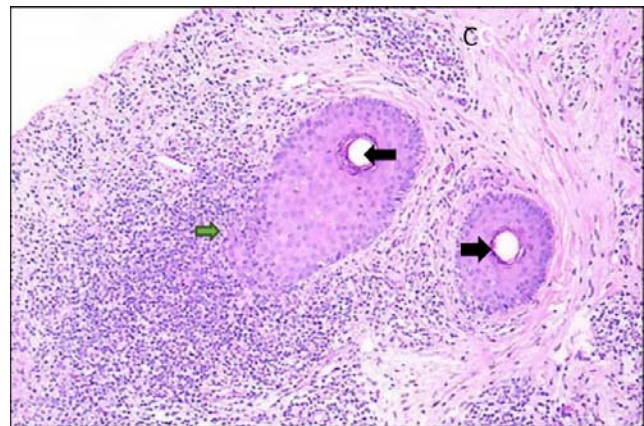
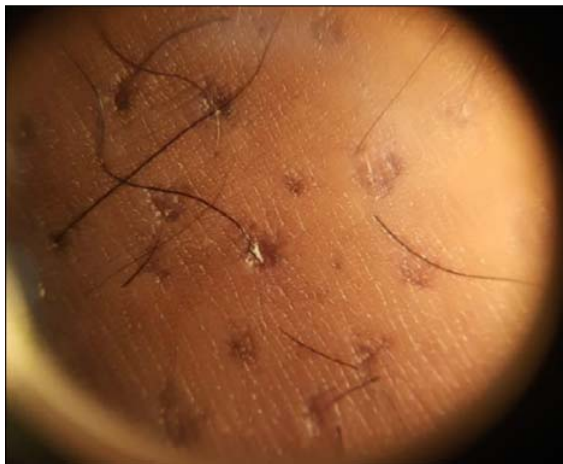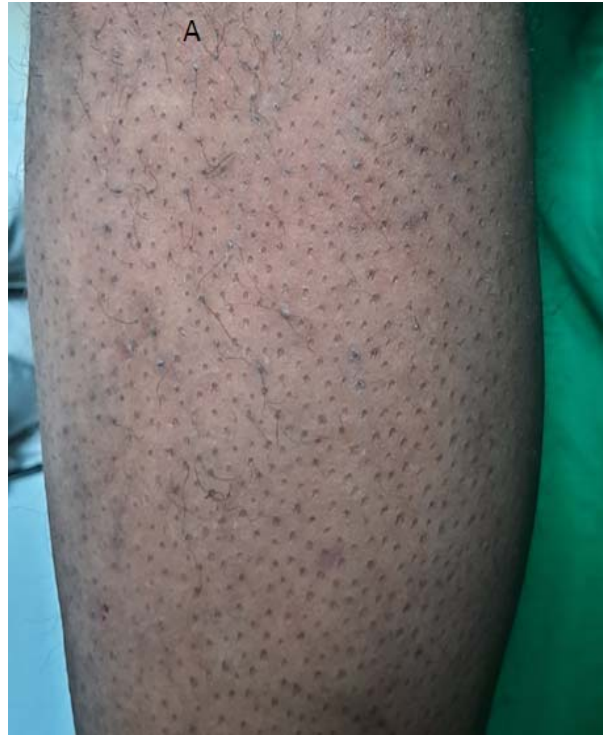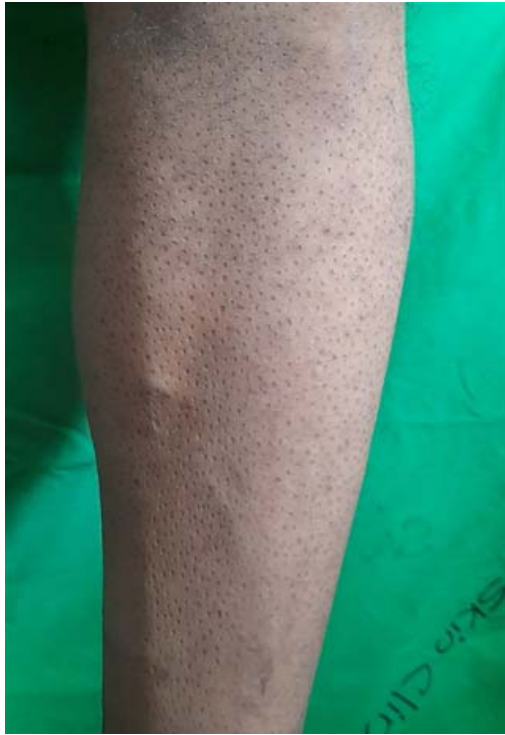Dermatoscopy guided skin biopsy of intact hair follicle for histopathology and immunofluorescence was done to support the clinical diagnosis of LPP and to exclude DLE as a cause for scarring alopecia. Basic haematological and biochemical profile was normal and ANA was negative. Skin biopsy revealed a lichenoid infiltrate predominate around hair follicles.

Since the disease was currently not active he was started on topical corticosteroids and doxycycline after patient education.

## Discussion

LPP is the follicular representation of lichen planus which is the prototype of CD8+ T cell mediated inflammatory diseases. LPP is not an uncommon disease with its salient feature of scarring alopecia. Though the follicular involvement with resultant scarring alopecia is the key clinical feature, non scarring type of alopecia also can be associated in certain variants like l'assueur-graham-little-

<sup>1</sup>Senior Registrar in Dermatology, <sup>2</sup>Registrar in Dermatology, <sup>3</sup>Consultant Dermatologist, Colombo South Teaching Hospital, Kalubowila, Sri Lanka.



A, B: Follicles replaced with atrophic scar and few remaining keratotic papules, C: Dermatoscopic view black arrow pointing atrophic white dot and green arrow pointing a tubular structure, D: H & E section, black arrow pointing perifollicular lichenoid infiltrate.

piccardi (LGLP) syndrome. Hair follicles of the scalp are the classic target than the follicles on other sites in LPP but the reason for this is unknown<sup>2</sup>. Also, the pattern of hair follicular involvement in scalp is highly variable.

However, in classic LPP body hair involvement has been poorly described but non-inflammatory type of

alopecia in pubic, axillary and eyebrow hair has been described in other variants of LPP such as frontal fibrosing alopecia<sup>3,5</sup> and LGLP.

In modern day medicine accurate diagnosis is the key element in patient care because of the availability of multiple management options for any given disease once diagnosed.

In our patient the diagnosis had been missed for many years probably due to the rarity of this presentation in LPP and late presentation for medical care with burnt out nature of the disease due to comparatively less cosmetic disfigurement. However salient features in history such as intense pruritus at the onset, follicular involvement with resultant scarring alopecia and examination findings such as perifollicular erythema and scaling, dermatoscopic features such as perifollicular scale, tubular structures and fibrotic white dots should alert the possibility of LPP.

If the patient had other evidences of lichen planus such as skin and mucosal lesions and hair and nail involvement the diagnosis would be straight forward. But in a patient without evidence of background lichen planus like in our patient the diagnosis is very challenging.

Herein with this case report we would like to emphasize the importance of the proper history taking and examination in the diagnostic process. Regardless of the rarity of the disease the diagnosis will be guided by the key features elicited in history and examination.

## References

1. Soares VC, Mulinari-Brenner F, Souza TE. Lichen planopilaris epidemiology: a retrospective study of 80 cases. *An Bras Dermatol*. 2015; **90**: 666-70. [PMC free article] [PubMed] [Google Scholar]
2. Pirmez R, Donati A, Valente NS, Sodre CT, Tosti A. Glabellar red dots in frontal fibrosing alopecia: a further clinical sign of vellus follicle involvement. *Br J Dermatol*. 2014; **170**: 745-6. [PubMed] [Google Scholar]
3. Mathur M, Acharya P, Karki A, Shah J, Nisha KC. Tubular Hair Casts in Trichoscopy of Hair and Scalp Disorders. *Int J Trichology*. 2019; **11**(1): 14-19. doi: 10.4103/ijt.ijt\_77\_18
4. Kaimal S, D'Souza M, Kumari R. Dermatitis cruris pustulosa et atrophicans. *Indian J Dermatol Venereol Leprol* 2009; **75**: 348-55.
5. Damia L, Vendramini, Bruno RL, Silveira, Bruna Duque-Estrada, Ana Letícia Boff, Celso Tavares Sodré, Rodrigo Pirmeza. Isolated Body Hair Loss: An Unusual Presentation of Lichen Planopilaris. *Skin Appendage Disord*. 2017; **2**(3-4): 97-9.