

Acitretin and pityriasis rubra pilaris – can we challenge deranged liver?

W K B A Fernando¹, K D T Dinupa², B E S Dahanayake¹, W N C Perera³

Sri Lanka Journal of Dermatology, 2021, 22: 52-54

Introduction

Pityriasis Rubra Pilaris (PRP) is a rare chronic inflammatory papulosquamous disease. It has variable clinical presentations with six subgroups¹. We describe a patient presented with PRP type 1 with altered liver functions and dyslipidemia successfully treated with acitretin. Acitretin is considered first-line therapy², although it has relative contraindications in patients with altered liver functions and may result in dyslipidemia and liver damage as a complication. Vigilant use of acitretin may be beneficial in a resource-poor setting to treat PRP.

Case report

A 63-year-old obese female presented with a six-week history of mildly itchy, diffuse erythematous skin eruption that first appeared on the face, then gradually spread to involve nearly 40% of the body surface area.

She had not been previously screened for diabetes mellitus and dyslipidemia and was not on any medication. Physical examination revealed erythematous scaly plaques with islands of sparing and perifollicular keratotic papules were noted (Figure 1). Palmar-plantar keratoderma was a prominent feature with a yellowish hue. She did not have scalp involvement or nail changes suggestive of psoriasis or any other signs and symptoms of an underlying malignancy.

Clinical diagnosis of Pityriasis Rubra Pilaris (PRP) type 1 was made, and histology of the skin biopsy revealed hyperkeratosis, alternating parakeratosis, and orthokeratosis, normal granular layer confirming the clinical diagnosis.

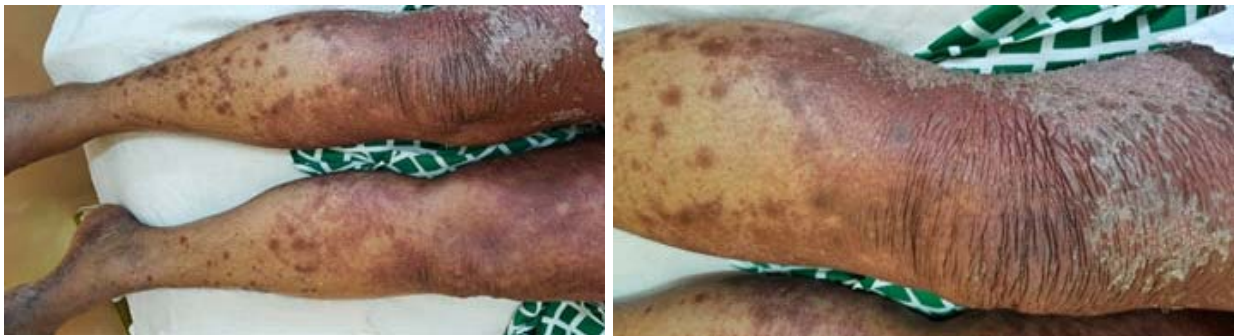


Figure 1. Erythematous scaly plaques with islands of sparing perifollicular keratotic papules involving both lower limbs.

Laboratory investigations included a complete blood count, thyroid function tests, ESR, renal function test, serum electrolyte, blood urea, and serum creatinine were within normal limits. Her fasting blood sugar was 228 mg/dl, HbA1c 8.4%, and lipid profile showed 270mg/dl, total cholesterol with increased triglyceride levels up to 260mg/dl, Grade 2 fatty liver was revealed on Ultrasound scan. The retroviral screening was negative. Her liver transaminases were elevated with ALT 135 IU/L AST 73 IU/L, probably due to non-alcoholic fatty liver.

¹Registrar in Dermatology, ²Senior Registrar in Dermatology, ³Consultant Dermatologist, Colombo South Teaching Hospital, Kalubowila, Sri Lanka

She was initially started on topical therapy, which included emollients, topical calcipotriol betamethasone combination, and 4% salicylic acid ointment as a keratolytic agent.

Her glycaemic control and dyslipidemia were optimized with lifestyle modifications, oral metformin and lipid-lowering drugs. Vitamin E³ and Omega-3 supplementation⁴ were also added to her treatment regime. After three weeks of therapy, her ALT decreased to 63 IU/l AST to 45IU/l, which improved steatosis and inflammation to lifestyle modifications and medications⁵. Her triglyceride levels fasting blood sugar were normal. However, her skin lesions did not exhibit significant improvement.

Despite the background history of Grade 2 fatty liver dyslipidemia disarranged liver enzymes, She was started on acitretin 20 mg daily. Her liver and lipid profiles were monitored twice weekly for the first 2 months of therapy, then every 3 months. There was a marked improvement in skin lesions with stable liver function and lipid levels six weeks after commencing acitretin (Figure 2).

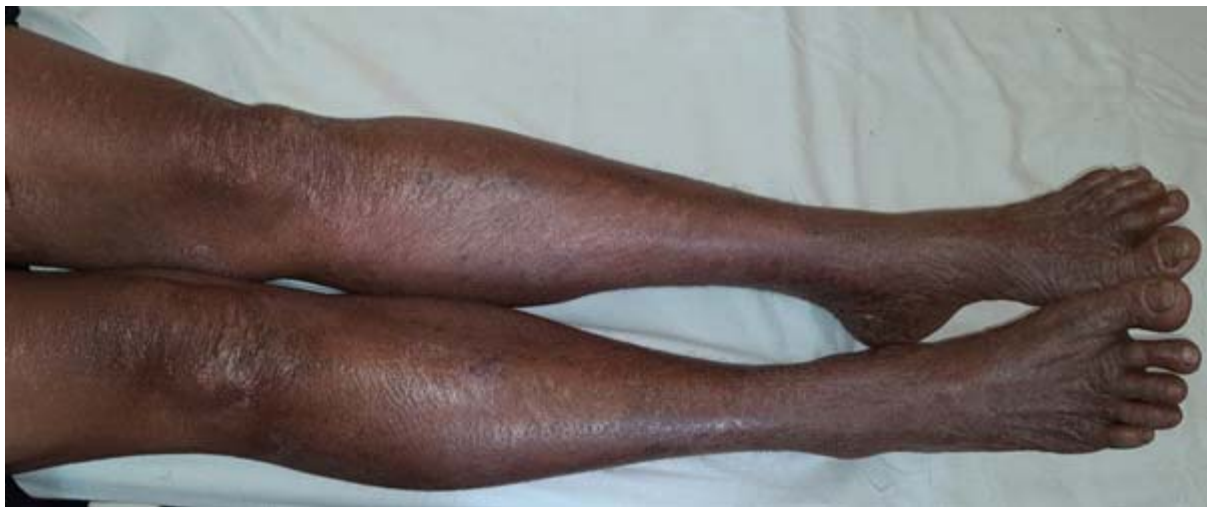

Figure 2. Resolved cutaneous skin lesions over bilateral legs.

Discussion

PRP is a rare chronic papulosquamous disease with unknown aetiology, characterized by coalescing scaly plaques, perifollicular keratotic papules, and islands of normal skin. Palmar plantar keratoderma with a yellowish hue is a distinctive clinical finding. There are six clinical variants described in the literature, 6th type in association with HIV. Adult type 1 PRP is the most typical variant¹.

Treatment of PRP is challenging; Isotretinoin, acitretin, methotrexate, cyclosporin, and biologics such as etanercept (TNF alpha-blocker), ustekinumab (IL-12/IL-23 blocker), and secukinumab (IL-17 blocker) are the available systemic treatment option with variable results².

Acitretin is considered first-line therapy, although it has relative contraindications in patients with altered liver functions and may result in dyslipidemia and liver damage as a complication. The most common adverse effects of retinoids are xerosis, cheilitis, hyperlipidemia, transaminase elevation, and bone fragility. We managed to treat our patient successfully with acitretin by vigilant monitoring for side effects. Liver enzymes every 2-4 weeks for the first 2 months of therapy and then every 3 months. If abnormal results are obtained, weekly checks should be instituted and the acitretin dose adjusted accordingly. Acitretin should be discontinued if transaminases are elevated to three times their normal upper limit, and patients with bilirubin greater than 50 $\mu\text{mol/L}$ or alanine aminotransferase greater than 200 iu/L ⁶.

References

1. Bologna J., n.d. *Dermatology* Volume 1. 4th ed. p.166.
2. Bologna J., n.d. *Dermatology* Volume 2. 4th ed. p.2210.
3. Chalasani N, Younossi Z, Lavine JE, Charlton M, Cusi K, Rinella M, Harrison SA, Brunt EM, Sanyal AJ. The diagnosis and management of nonalcoholic fatty liver disease: Practice guidance from the American Association for the Study of Liver Diseases. *Hepatology*. 2018; **67**(1): 328. Epub 2017 Sep 29. Review article: omega-3 fatty acids - a promising novel therapy for non-alcoholic fatty liver disease. Masterton GS, Plevris JN, Hayes PC *Aliment Pharmacol Ther*. 2010; **31**(7): 679.
5. Croci I, Coombes JS, Bucher Sandbakk S, Keating SE, Nauman J, Macdonald GA, Wisloff U. Non-alcoholic fatty liver disease: Prevalence and all-cause mortality according to sedentary behaviour and cardiorespiratory fitness. The HUNT Study. *Prog Cardiovasc Dis*. 2019; **62**(2): 127. Epub 2019 Feb 21.
6. British Association of Dermatologists guidelines on the efficacy and use of acitretin in dermatology. *British Journal of Dermatology* 2010; **162**: 952-63.